ARDS as a presenting feature in sarcoidosis: an uncommon occurrence

Sanjeet K. Shrestha[1], Jonas Malla[1], Yuvaraj Bhusal [1], Sanjeet Bhattarai [1], Rakesh Lama[1], Sulav Rayamajhi[1], Naresh Gurung[1], Ashish Shrestha[1], Ashish Karthik[1], Pratistha Pradhan[1], Reena Rana[2], Khusboo Khetan[2].

[1.] Department of Pulmonary, Critical Care and Sleep Medicine, Nepal Mediciti Hospital
[2.] Department of Laboratory Medicine and Pathology , Nepal Mediciti Hospital

This work is licensed under a Creative Commons Attribution 4.0 Unported License.

ABSTRACT:

Sarcoidosis though a chronic multi-system granulomatous disease, predominantly involves respiratory system. Often asymptomatic, patients can present with lymphadenopathy, prolonged fever and shortness of breath. Acute respiratory distress syndrome (ARDS) is relatively uncommon presenting feature of the disease. Here we present a case of a 19 years old female presenting in acute respiratory distress syndrome, eventually being diagnosed as Sarcoidosis. Although different diagnostic criteria have been developed for early diagnosis of sarcoidosis, atypical presentations can always pose significant challenge and lag for the diagnosis.

Keywords: Sarcoidosis, Acute Respiratory Distress Syndrome, Granuloma

INTRODUCTION:

Sarcoidosis, a chronic granulomatous disease, can affect multiple organ systems. The etiology is largely unknown and it predominantly affects the respiratory system. Histological distinction of Sarcoidosis remains the presence of non-caseating granulomas in the affected organ. It was first reported by Jonathan Hutchinson in 1869 in a coal wharf worker who presented with skin lesions[1]. Sarcoidosis, initially considered the disease of the developed countries, has now shown steady rise in the developing countries. Diagnosing sarcoidosis in developing countries remains difficult due to the overwhelming focus on infectious cause including tuberculosis. Atypical presentations such as ARDS and neurologic manifestations as the sole presenting feature make it even more difficult to reach a confirmative diagnosis. Here we describe a case of a young female patient with sarcoidosis presenting as ARDS.

CASE:

A 19 years old female presented to the Out patient unit with the history of fever with chills and rigor for 10 days and shortness of breath for 3 days. She was initially evaluated at a primary center for tropical fever and was started on antimalarial and antibiotic. Despite initial therapy, her symptoms worsened and subsequently, she was referred to our center for further management.

At presentation, she had tachypnea, tachycardia and hypoxia (SpO2: 79% in room air). Examination revealed hepatosplenomegaly. Tropical disease screening for enteric fever, malaria, dengue, leptospirosis, brucellosis, and scrub typhus came negative. Blood culture was negative as well. USG abdomen showed hepatosplenomegaly with periportal lymph node enlargement. Echocardiography was normal. Arterial blood gas revealed a pH of 7.36, PaCO2 of 44 mmHg and PaO2 of 58 mm Hg at FiO2 of 40%. High resolution computed tomography scan showed bilateral diffuse ground glass opacification with air space consolidation in bilateral lower lobes suggesting ARDS (Figure 1). She was treated with high flow oxygen, antibiotics and steroids. With three 16-hour sessions of awake self proning, she showed significant improvement in oxygenation as well as radiological clearance in HRCT scan. She was discharged on the 9th day of admission on oral steroid and antibiotics. Follow-up after a week was uneventful without new symptoms. The steroid was gradually tapered and stopped.

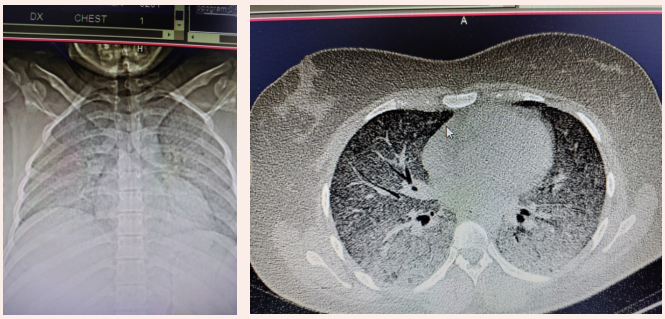

Figure 1. Chest CT showing diffuse ground glass opacification in both lungs with dependent air space consolidation in bilateral lower lobes

Corresponding author:
Dr Sanjeet Krishna Shrestha
shrestha.sanjeet@gmail.com

Unfortunately, two weeks later she presented in outpatient clinic with recurrence of fever and headache. Symptomatic management with antipyretic-analgesic didn't relieve her symptoms. Few days later, she landed in the emergency department disoriented and agitated. She had suffered an episode of generalized tonic clonic seizure. Emergency management was commenced immediately. Neurology consultation was done. CT scan of head didn't reveal any abnormal findings. She was admitted in high dependency unit. Her CSF analysis was normal. MRI brain done 24 hours later showed widespread multiple nodular lesions in the cerebrum, midbrain and cerebellum (figure 2). LDH level was normal. Her angiotensin converting enzyme level was significantly raised (125U/L). Bone marrow aspiration and biopsy examination showed non-caseating granulomas strongly suggestive of sarcoidosis (figure 3). She showed significant improvement with steroids and newer generation antipsychotic and was discharged from hospital. Currently, she is in good remission with low dose of prednisolone, azathioprine and quetiapine and is under regular follow up at our respiratory and neurology clinic.

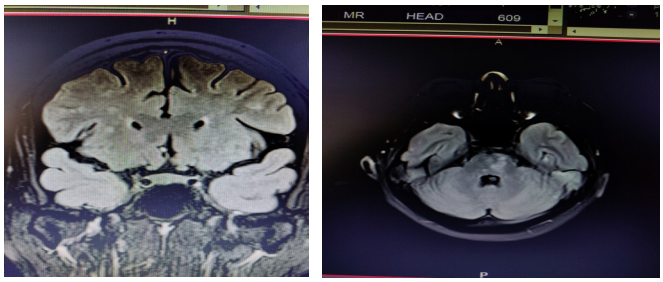

Figure 2. MRI showing innumerous tiny enhancing nodular lesions in brain including cerebellum along with punctate and patchy enhancing areas in brainstem associated with minimal leptomeningeal enhancement over cerebral convexities.

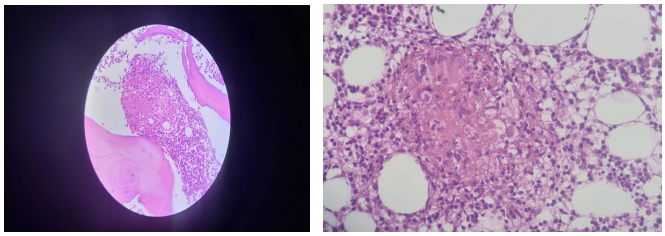

Figure 3. Bone marrow biopsy showing epitheloid cell non-caseating granuloma (magnification: 10 X and 70 X respectively)

DISCUSSION:

Sarcoidosis can involve various organs with variable presentations in the respective organs (table 1). The patients usually present with a history of prolonged fever, shortness of breath and lymphadenopathy.

System	Percentile
Pulmonary	90-95%
Liver	11.5-21%
Spleen	6.7-18%
eyes	11.8-21%
Nervous system	4.6-5.1%
cardiac	2.3-5.1%
Lymph node	15.2-73%

Table 1. Organ involvement in sarcoidosis

Lungs are the most commonly affected organs in sarcoidosis[2,3]. However, ARDS as a presenting feature of sarcoidosis is a rare occurrence and only few cases have been documented in literature [4-7]. According to the Berlin criteria, our patient had moderate ARDS. Although it can be argued that the patient was not under any form of ventilation, literature review shows that spontaneous breathing patients can be recognized with ARDS at an early stage without positive pressure ventilation[8,9].

Neurosarcoidosis is an uncommon but fatal complication of sarcoidosis[10,11]. Cranial nerve palsies are common presenting features and seizures complicates the clinical picture in almost 5-10 % of the cases[12,13]. Neurosarcoidosis requires compatible clinical findings with histologic demonstration of non-caseating granulomas and exclusion of other diseases. MRI usually shows leptomeningeal involvement however lobar involvement is rare[14]. MRI done in our patients showed multiple nodules all over the brain which warranted exclusion of other major possibilities such as tuberculosis and lymphoma. Bone marrow biopsy examination showed non-caseating granulomas. Normal CSF findings, significantly raised ACE levels and bone marrow biopsy revealing non-caseating granuloma lead the diagnosis of sarcoidosis with a diagnostic lag of 2 months. In retrospection, significant response of ARDS and neurological issues to steroids can be attributed to alveolar and neurosarcoidosis[15].

CONCLUSION:

Sarcoidosis can present with wide range of, often unusual clinical features frequently leading to a significant diagnostic lag. ARDS remains a rare presenting feature of the disease.

Although different criteria have been developed for early diagnosis of sarcoidosis, biopsy remains the most confirmative option. Sound knowledge of the disease and detailed workup can lead to an early diagnosis and treatment.

REFERENCES:

1. James DG, Sharma OP. From Hutchinson to now: a historical glimpse. Current opinion in pulmonary medicine. 2002 Sep 1;8(5):416-23.
2. Baughman RP, Teirstein AS, Judson MA, Rossman MD, Yeager H Jr, Bresnitz EA, DePalo L, Hunninghake G,

Iannuzzi MC, Johns CJ, McLennan G, Moller DR, Newman LS, Rabin DL, Rose C, Rybicki B, Weinberger SE, Terrin ML, Knatterud GL, Cherniak R; Case Control Etiologic Study of Sarcoidosis (ACCESS) research group. Clinical characteristics of patients in a case control study of sarcoidosis. Am J Respir Crit Care Med. 2001 Nov 15;164(10 Pt 1):1885-9.

3. Mayock RL, Bertrand P, Morrison CE, Scott JH. Manifestations of sarcoidosis: analysis of 145 patients, with a review of nine series selected from the literature. The American journal of medicine. 1963 Jul 1;35(1):67-89.
4. Sahn SA, Schwarz MI, Lakshminarayan S. Sarcoidosis: the significance of an acinar pattern on chest roentgenogram. Chest. 1974 Jun 1;65(6):684-7.
5. Sabbagh F, Gibbs C, Efferen LS. Pulmonary sarcoidosis and the acute respiratory distress syndrome (ARDS). Thorax. 2002 Jul 1;57(7):655-6.
6. Chirakalwasan N, Dallal MM. Pulmonary sarcoidosis presenting with acute respiratory failure. Southern medical journal. 2005 Mar 1;98(3):382-5.
7. Shibata S, Saito K, Ishiwata N, Ieki R. A case of sarcoidosis presenting with high fever and rash progressing to acute respiratory failure. J Japanese Respir Soc. 2007;45(9):691–7.
8. Coudroy R, Frat JP, Boissier F, Contou D, Robert R, Thille AW. Early identification of acute respiratory distress syndrome in the absence of positive pressure ventilation: implications for revision of the Berlin criteria for acute respiratory distress syndrome. Critical care medicine. 2018 Apr 1;46(4):540-6.
9. Matthay MA, Thompson BT, Ware LB. The Berlin definition of acute respiratory distress syndrome: should patients receiving high-flow nasal oxygen be included? Lancet Respir Med. 2021 Aug;9(8):933-936. [PubMed] [Article]
10. Joseph FG, Scolding NJ. Neurosarcoidosis: a study of 30 new cases. Journal of Neurology, Neurosurgery & Psychiatry. 2009 Mar 1;80(3):297-304.
11. Scott TF. Neurosarcoidosis: progress and clinical aspects. Neurology. 1993 Jan 1;43(1 Part 1):8-12.
12. Oksanen V. Neurosarcoidosis: clinical presentations and course in 50 patients. Acta Neurologica Scandinavica. 1986 Mar;73(3):283-90.
13. Pawate S, Moses H, Sriram S. Presentations and outcomes of neurosarcoidosis: a study of 54 cases. QJM: An International Journal of Medicine. 2009 Jul 1;102(7):449-60.
14. Nozaki K, Judson MA. Neurosarcoidosis: clinical manifestations, diagnosis and treatment. La Presse Médicale. 2012 Jun 1;41(6):e331-48.
15. Ceuppens JL, Lacquet LM, Marien G, Demedts M, Van Den Eeckhout A, Stevens E. Alveolar T-cell subsets in pulmonary sarcoidosis. Correlation with disease activity and effect of steroid treatment. The American review of respiratory disease. 1984 Apr 1;129(4):563-8.